

SECONDARY PROCEDURES FOR A-V FISTULA FAILURE

G Kootstra

*University of Limburg, Hospital St Annadal,
Maastricht, The Netherlands*

Summary

There is a progressive increase of patients in the dialysis population in whom primary access by a Brescia-Cimino A-V fistula is no longer possible. These patients require secondary access procedures. Instead of using graft material several alternatives exist using the patient's own venous and arterial remnants, as morbidity and mortality of these procedures will be less than those where graft material is used. Long term patency rates of graft fistulae are disappointing, partially due to the damage to the graft by repeated punctures. A new device, which avoids needling, is briefly mentioned.

Introduction

Maintenance of access for haemodialysis continues to be a problem for patients and medical staff. With the acceptance of patients with diabetes mellitus and elderly patients for haemodialysis the problems have increased. There is hardly a dialysis centre without a certain percentage of patients in whom the standard A-V fistula of Brescia and Cimino [1] no longer provides satisfactory access. So-called secondary access procedures have become necessary for between 10 and 20 per cent of the dialysis population [2, 3]. This paper deals with this problem of secondary access and it intends to direct attention to previous published alternatives using the patients' own material instead of the application of widely advertised graft material.

Nomenclature

The term *primary* access surgery will be restricted to those procedures where an A-V fistula as described by Brescia and Cimino or any variant using the radial artery and the cephalic vein distally at the wrist, has been constructed.

The term *secondary* access surgery covers all other procedures where arteries and veins are connected to each other, with or without the use of graft material.

The use of catheters, either in the groin or at the site of the subclavian vein is not covered by this definition. In describing these procedures as acute one would fail to note that interesting studies have been published on the long term use of these catheters [4].

Secondary access procedures

The different possibilities for secondary access procedures are listed in Table I. As the catheter and the A-V shunt are not included in this paper, they will not be discussed. However, it should be stressed that it is particularly the catheter and the A-V shunt which should be used to gain temporary access in those patients who are candidates for secondary access procedures.

TABLE I. Secondary access procedures

0	Catheter and A-V shunt
I	Transposition of forearm veins
II	A-V fistula at the elbow
III	Graft fistula
IV	Button technique

A secondary access procedure should be carefully planned. It should be electively scheduled on the theatre list and the patients should have had one or two sessions of successful haemodialysis performed by a temporary access. Angiographic studies on the remnants of arteries and veins are performed and anticoagulant medication is prescribed if indicated.

In a well planned performance one of the following group of procedures can be chosen.

Transposition of forearm veins (Figure 1)

When the cephalic vein and the distal part of the radial artery cannot be used for the reconstruction of a standard A-V fistula, the basilic vein on the ulnar and dorsal side of the forearm should be inspected and considered for transposition.

Three possibilities are available:

A distal end of vein to side of artery fistula of the basilic vein and ulnar artery

Two problems may be encountered: there are only small ramifications of the vein available for anastomosis and after construction of successful A-V fistula needle positioning may be difficult due to the position of the vein on the lateral aspect of the forearm.

A transposition of the basilic vein to the palmar side of the forearm and anastomosis to the remnant of the radial artery This procedure has been popularised by Lindstedt [5].

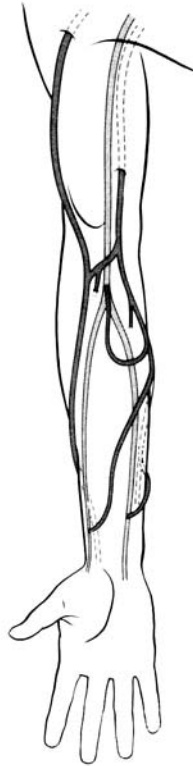

Figure 1. The three possibilities of performing an A-V fistula with the basilic vein of the forearm

Transposition of the basilic vein into a subcutaneous loop, with an end of vein to side of brachial artery anastomosis The group of Kinnaert had a patency rate of two out of three functioning fistulae at two years [6].

A-V fistula at the elbow

Quite often one or two veins at the elbow fold are still available when forearm veins and arteries have all become destroyed by previous access procedures. The first impression might be to construct an A-V fistula with one of the major veins; however, there is a less well known alternative which should be tried first, the A-V fistula described by Gracz [7].

Perforating vein fistula (Gracz) There is at the elbow fold a side branch of the median cubital vein (usually, but there are variations) which perforates the fascia and enters the deep venous system. Gracz used this perforating vein for a fistula by connecting it end to side to the brachial artery. He resects the involved part

of the deep system to provide a patch at the end of the vein. Slooff [3] prefers not to damage the deep system and just ligates the end of the perforating vein. The diameter of the remaining end of the vein is sufficient to perform an end-to-side anastomosis. The A-V fistula results in arterialisation of the entire superficial venous system which has not been previously destroyed. There is a valve in the distal direction of the venous system, thereby protecting the distal system. Either this valve can be destroyed at the procedure or it will become incompetent in the long term by venous distension. Moris [6] reported a 100 per cent patency at two years with this elbow A-V fistula.

Median cubital vein end-to-side to brachial artery.

Cephalic vein end-to-side to brachial artery Both these procedures have a less favourable reputation because such an A-V fistula tends to have several complications such as haemodynamic (steal syndrome, ischaemia of the hand) and anatomic (aneurysm formation). Patency rates are rather low. Moris [6] calculated a patency rate of about 50 per cent at two years. Nevertheless, the severity of the haemodynamic complications is mostly mild and they tend to decrease in time.

Subcutaneous transposition of the basilic vein and end-to-side to brachial artery The basilic vein continues its course under the superficial fascia of the upper arm. It can be repositioned to the subcutaneous space and then anastomosed end-to-side to the brachial artery. Moris [6] reports a patency rate of two out of three at two years.

In all these previously mentioned A-V fistulae (Figure 2) there is a rather short length of vein available for puncture and the positioning of two needles is usually difficult. Therefore a one needle system is frequently necessary in these A-V fistulae at the elbow.

Reverse A-V fistula In 1977 Geis et al [8] described the reverse A-V fistula. The basilic vein is connected side-to-side to the brachial artery, at a level proximal to the elbow fold. The proximal part of the basilic vein is tapered and valves in the distal direction are destroyed to permit blood flow in a reverse direction. Shapira [9] reports a 76.9 per cent cumulative patency rate at two years in 20 adults. In one patient persisting oedema necessitated closure of the fistula.

Graft fistula

All A-V fistulae where graft material is used are considered. There are some major advantages in the use of graft material in secondary access. The most important one is the easy availability of the graft material, while another is the diversity in size and length available. Nevertheless, the patency rate drops linearly with time. Decurtins et al [10] report a reduction to 10 per cent patency at four years in a series of 99 Bovine® grafts, while Slooff [3] comes to the same negative results with PTFE grafts. A common complication is infection and this can turn into a major disaster with sepsis, mycotic aneurysm and bleeding. In nearly all cases

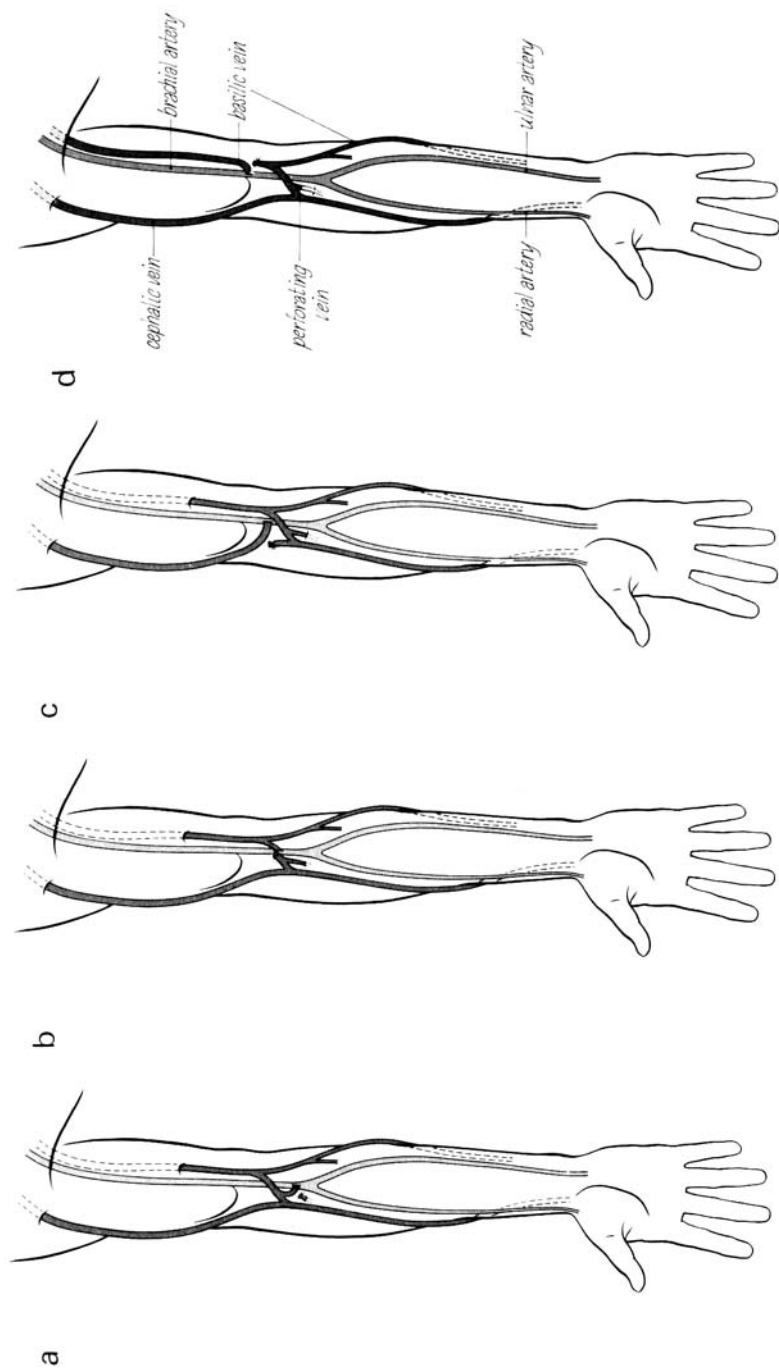


Figure 2. The four possibilities of constructing an A-V fistula at elbow level. (a) Perforating vein fistula (Gracz); (b) Median cubital vein end-to-side to brachial artery; (c) Cephalic vein end-to-side to brachial artery; (d) Subcutaneous transposition of the basilic vein and end-to-side anastomosis to brachial artery

wherein graft material has been used, phlebosclerosis will develop at the venous anastomosis. This results in a gradual increase in pressure at the venous side inducing thrombosis.

The producers of the graft material claim properties of their material superior to that of others, and there are some slight differences, not just in patency rate, but in biocompatibility. However, hardly any material is resistant to repeated puncture which destroys the structure of the material. Research into graft material with more specific attention to the problem of the damage by the repeated punctures should be initiated.

The available graft material is listed in Table II.

TABLE II. Available graft material

-
1. Saphenous vein
Autologous
Homologous Vascogref®
 2. PTFE
Impra®
Gore-Tex®
 3. Bovine graft
Artegraft®
Solco-P®
 4. Human umbilical vein
Dardik®
-

Button technique

Recently, a new device in vascular access surgery has been introduced. Two companies are presenting the device (constructed of different material) under the name of Hemasite® and Biocarbon®. The device consists of a button that is connected by a graft or directly to the blood vessel; only the button comes out of the skin and can be seen. The dialysis lines are plugged into the button and so access is obtained. There is no needling of the graft. It is too early to advocate its wide use, but experience is increasing, and it might become an alternative in desperate cases.

References

- 1 Brescia MJ, Cimino JE, Appel K, Hurvich BJ. *N Engl J Med* 1966; 275: 1089
- 2 Morgan A, Dammin GJ, Lazarus JM. *Trans ASAIO* 1978; 24: 44
- 3 Slooff MJH. *Neth J Surg* 1982; *Suppl.*
- 4 Vanholder R, De Clippele M, De Cubber A, Ringoir S. *Access Surgery* 1982. In press. Lancaster, UK: MTP Press
- 5 Lindstedt E, Lindergard B. *Scand J Urol Nephrol* 1980; 14: 207
- 6 Moris C, Kinnaert P. *Access Surgery* 1982. In press. Lancaster, UK: MTP Press

- 7 Gracz KC, King TS, Soung LS et al. *Kidney Int* 1977; 11: 71
- 8 Geis WP, Giacchino JL, Twatsuki S et al. *Surg Gynecol Obstet* 1977; 145: 901
- 9 Shapira Z, Shmueli D, Yussim A, Servadio C. *Access Surgery* 1982. In press.
Lancaster, UK: MTP Press
- 10 Decurtins M, Buchmann P, Uhlschmid G, Largiader F. *Access Surgery* 1982. In press.
Lancaster, UK: MTP Press

Address for correspondence: G Kootstra, Department of Surgery, University of Limburg, Hospital St Annadal, Maastricht, The Netherlands