

THE ISOLATED C₃ IN THE 'VASCULAR POLE' IN PATIENTS WITH PRIMARY HAEMATURIA

P Barceló, A Covarsi, JA Ballarin, JL Rodriguez*, C Gelpi*, G Del Rio

*Fundacion Puigvert, Universidad Autonoma de Barcelona and
Hospital de la Santa Cruz y San Pablo, Spain

Summary

Among sixty-four patients with primary haematuria, immunofluorescence methods revealed seven cases (11%) with isolated C₃ deposits in the 'vascular pole'. Serum complement were normal and the follow-up after 20–41 months indicate a benign course. In patients with C₃ deposits in the 'vascular pole' light microscopy was normal. We never observed C₃ deposits in specimens of normal kidney which were processed by the same methods using mono-specific antisera confirmed by immunoelectrophoresis. This entity defined by immunofluorescence methods, can be called 'vascular pole disease'.

Introduction

Primary haematuria remains a diagnostic problem for the clinician. This term includes patients with persistent or recurrent haematuria in the absence of genitourinary or systemic diseases, normal function and without or with minimal proteinuria.

Renal biopsy shows minor glomerular alterations, mesangial proliferation or irregular thickness of the capillary membrane. The immunofluorescence findings identify IgG, IgA, IgM, C₃ fibrinogen in the capillary walls, mesangium or interstitium in most cases [1,2]. The IgA nephropathy [3] or recently mesangial IgM deposits have been described [4].

We observed in some patients with primary haematuria isolated deposits of C₃ in the 'vascular pole'; their clinical and immunopathologic findings will be described.

Material and methods

Renal biopsy was performed in sixty-four patients with primary renal haematuria. Tissue was processed for light and immunofluorescence microscopy using

specific antisera for IgG, IgA, IgM, C₃ and fibrinogen.

The age range from seven to 49 years with an average of 20.3 ± 10.3 years. Fifty were male and fourteen female. Macroscopic haematuria was evident in 42 cases and microscopic in 22. None of the patients was hypertensive, creatinine clearances were normal and urine protein was not observed or was less than 0.20g/24 hours.

Serum concentrations of immunoglobulins IgG, IgA, IgM, C₃, C₄, Clq and CH₅₀ components of complement were measured by means of immunodiffusion plates. Additionally studies included tests for antinuclear antibody, cryoglobulins and circulating immunocomplexes (polyethyleneglycol).

Seven specimens of normal kidney were obtained by surgery (lithiasis, pole tumours, cysts) and were processed by light and immunofluorescence microscopy.

Results

Forty-two cases presented macrohaematuria and 22 had isolated microhaematuria (10 persistent and six recurrent). No family history of haematuria or deafness were found. In all cases pyelography was normal, and other explorations: cystoscopy (15), arteriography (7) etc showed no urological lesions.

The light and immunological results are summarised in Tables I and II.

TABLE I. Light microscopy in 64 patients with primary haematuria

Minimal changes	42	66%
Focal and segmental mesangial hypercellularity	8	12%
Diffuse mesangial hypercellularity	9	14%
Segmental increase in mesangial matrix	4	6%
Segmental glomerulosclerosis	1	1%

TABLE II. Immunofluorescence results in 64 patients with primary haematuria

	Number	IgG	IgM	C ₃	V.P.	Mesangial	Interstitial Vessels C ₃
Negative immunofluorescence	20	-	-	-	-	-	3
IgA nephropathy	25	6	3	1		19	5
Mesangial IgM	7	-	7	2		1	3
Mesangial C ₃	6	-	-	1		6	1
C ₃ in the 'Vascular Pole'	7	-	-	7		1	4

In seven patients the only finding (Figure 1) was an isolated C₃ deposition in the 'vascular pole' and light microscopy was normal or with minimal changes. High values of IgA were found in three of the 20 patients with minor lesions (15%), 13 with Berger's disease (58%); one with mesangial IgM (16%) and two with 'vascular pole' (32%). Increase of IgM was seen in two cases with minor lesions (10%), four Berger's disease (16%), six mesangial IgM (86%) and none

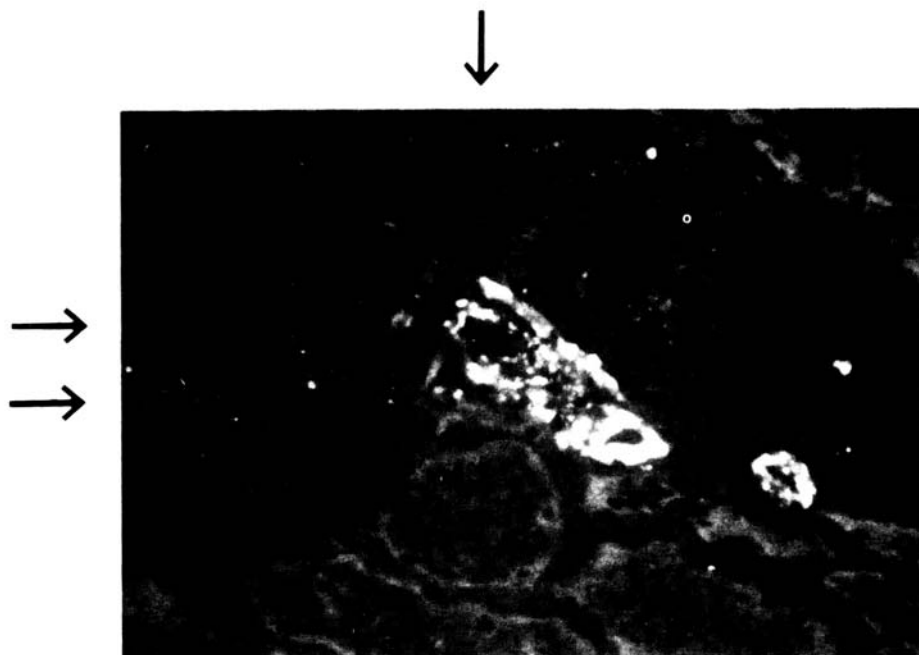


Figure 1. Granular C_3 deposit in the vascular pole. ↓ vascular pole. → cortical glomeruli

with deposits in the vascular pole. CH_{50} , Clq, C_3 and C_4 as well as the cryoglobulins, were normal in all cases.

In seven normal cases obtained by surgery, light microscopy was always normal and none showed deposits of C_3 in the vascular pole.

Discussion

Our results indicate that in seven patients (11%) with primary haematuria C_3 deposition in the 'vascular pole' has been observed. These deposits were always isolated and no other immunoglobulins could be seen in the glomeruli or in the blood vessels. The light findings show minimal changes and serum complement was normal in all cases.

Arteriolar C_3 deposition has already been reported in patients with recurrent or persistent haematuria [5,6], especially in cases with marked atherosclerosis or the loin-pain-haematuria syndrome [7]. Baumelou [6] found deposits of C_3 in blood vessels in 64% of cases with microhaematuria and recently Orfila [5] observed C_3 deposits in the 'vascular pole' associated with C_3 mesangial deposits.

In each case biopsy specimens were immediately frozen in liquid nitrogen and were cut in a cryostat to a thickness of $3\mu\text{m}$. The mono-specificity of all antisera was verified by manufacturers and confirmed by immunoelectrophoresis. Additionally in the tissue of normal kidneys, obtained at surgery, deposits of C_3 in the 'vascular pole', blood vessels or mesangium were never seen.

The follow-up of the seven cases showed no changes in the disease after 20–41 months following renal biopsy. No renal failure, hypertension or urologic disease was observed and only haematuria persisted.

The presence of C₃ in the 'vascular pole' in some cases with primary haematuria is difficult to explain. Recently C₃ receptors have been demonstrated on the visceral epithelium of the glomerulus. This fact may explain the deposits of C₃ [8] in diseases mediated by complement of C₃ trapping in a receptor disorder. Lesions in the endothelium can be a cause of C₃ deposits in blood vessels.

The presence of C₃ in the 'vascular pole' is an entity with a benign course which can be separated from the other causes of primary haematuria by immunofluorescence.

References

- 1 Pardo V, Berian MG, Levi DF et al. *Am J Med* 1979; 67: 817
- 2 Kupor LR, Mullins JD, McPhaul JJ. *Arch Intern Med* 1975; 135: 1204
- 3 Berger J, Hinglais J. *J Urol Nephrol* 1968; 74: 694
- 4 Bhasin HK, Abuelo JG, Navak R et al. *Lab Invest* 1978; 39: 21
- 5 Orfila C, Pieraggi MI, Suc JM. *Lab Invest* 1980; 43: 1
- 6 Baumelou A, Segonds A, Beaufils H et al. In Kuss R, Legrain M, eds. *Sem Urol Nephrol in Hematuries* 1981; 160. Paris: Masson
- 7 Fletcher P, Al-Khader AA, Parsons V et al. *Nephron* 1979; 24: 150
- 8 Pettersson EE, Bhan AK, Schneeberger EE et al. *Kidney Int* 1978; 13: 245

Address for correspondence: P Barcelo, Fundacion Puigvert, Universidad Autonoma de Barcelona, Barcelona, Spain