

GLOMERULAR DEPOSITS OF RHEUMATOID FACTOR IN GLOMERULONEPHRITIS

F Bartolomeo, A L'Abbate, C Martorano, V Misefari, A Caccamo, Q Maggiore

Centro di Fisiologia Clinica CNR, Reggio Calabria, Italy

Summary

One hundred and forty-four kidney biopsy specimens with various forms of glomerulonephritis were studied to assess the presence of Rheumatoid Factor (RF) deposits. RF deposits were found in 21 specimens: six with acute post-streptococcal glomerulonephritis, two with crescentic glomerulonephritis, four with lupus nephritis, eight with essential mixed cryoglobulinaemia glomerulonephritis, and one with end-stage kidney disease. Blocking and elution studies carried out on specimens with essential mixed cryoglobulinaemia provided evidence that the RF deposits derive from circulating monoclonal RF.

This data suggests that RF participates in the formation of glomerular immune deposits in several forms of immune complex mediated glomerulonephritis.

Introduction

Data on the participation of Rheumatoid Factor (RF) in the pathogenesis of immunologically mediated kidney disease are scarce [1-5].

We investigated this problem by examining renal biopsies to assess the frequency of RF deposits in various forms of glomerulonephritis, and to establish their nature in selected cases.

Patients and methods

Patients

One hundred and forty-four kidney biopsy specimens obtained from 142 consecutive patients were studied. According to clinical, laboratory, and immunohistopathological data renal biopsies were classified as indicated in Table I.

RF deposits

RF deposits were searched for in all specimens with a fluorescein labelled solution (3.0 - 5.5 mg/ml) of heat aggregated human IgG (FAIgG). The specificity control of the reaction with FAIgG was assessed by treating tissue

TABLE I. Frequency of RF deposits in various form of glomerulonephritis

	Specimens examined No.	RF positive No. (%)
Minimal change nephrosis	9	0 (0)
Focal glomerulosclerosis	13	0 (0)
Membranous GN	10	0 (0)
IgA Nephropathy	7	0 (0)
Acute post-streptococcal GN	16	6 (37)
Crescentic GN	6	2 (33)
Membranoproliferative GN	6	0 (0)
Lupus nephritis	17	4 (23)
EMC-GN	10	8 (80)
Liver disease with GN	14	0 (0)
Vasculitis	5	0 (0)
End-stage kidney disease	8	1 (12)
Tubulo-interstitial and other disorders	23	0 (0)
Total	144	21 (14)

sections with a preparation of non-fluorescein labelled aggregated IgG. To exclude Fc receptors or Clq deposits as the source of the positive reactions, we also examined tissue sections with a fluorescein labelled solution (3.0–5.5mg/ml) of aggregated alkylated and reduced IgG (A/R FAIgG) which is known to react with RF only [6–9].

To gain further information about the nature of RF deposits, we carried out blocking experiments (a) and elution studies (b).

- a) The tissue sections were exposed to unconjugated antisera against human IgG, IgA, IgM, and Clq before incubation with FAIgG [2].
- b) A surgical kidney specimen from a patient with essential mixed cryoglobulin-aemia (EMC) of IgG-IgM (*k*) type was eluted with 0.2M glycine buffer pH 2.4. The eluate, after being dialysed against acetate buffer and concentrated, was fractionated on Sephadex G-200 chromatography at 4°C in 0.1M acetate buffer pH 4.0. The collected fractions were analysed for serum proteins by double immunodiffusion and for RF activity by latex test [5].

Results

Representative examples of glomerular staining with FAIgG are shown in Figures 1 and 2. Staining was inhibited by pretreatment with labelled aggregated IgG.

RF deposits were detected in varying proportions of patients with acute post-streptococcal glomerulonephritis, crescentic glomerulonephritis, lupus nephritis, and EMC glomerulonephritis (Table I). Composition of glomerular

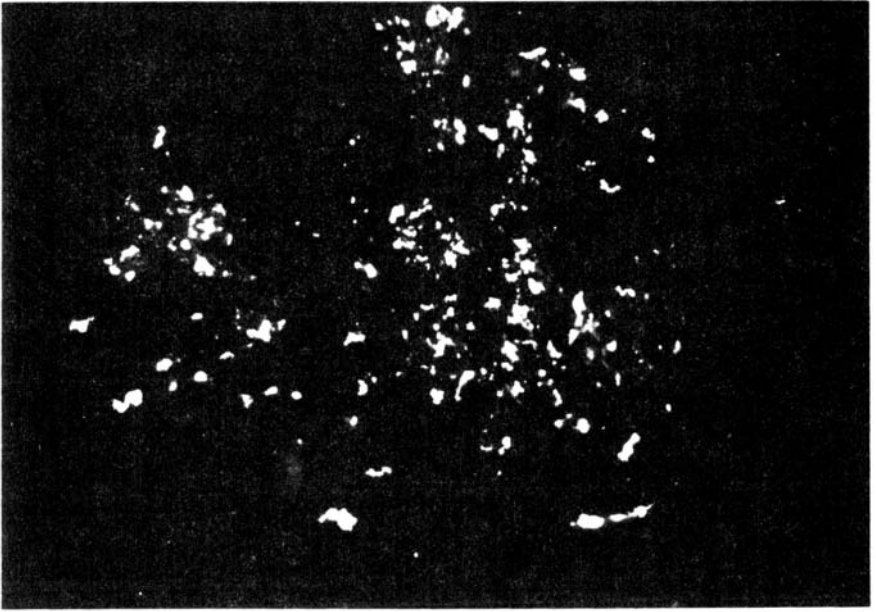


Figure 1. Diffuse glomerular staining with FAIgG in a case of acute post-streptococcal glomerulonephritis ($\times 290$)

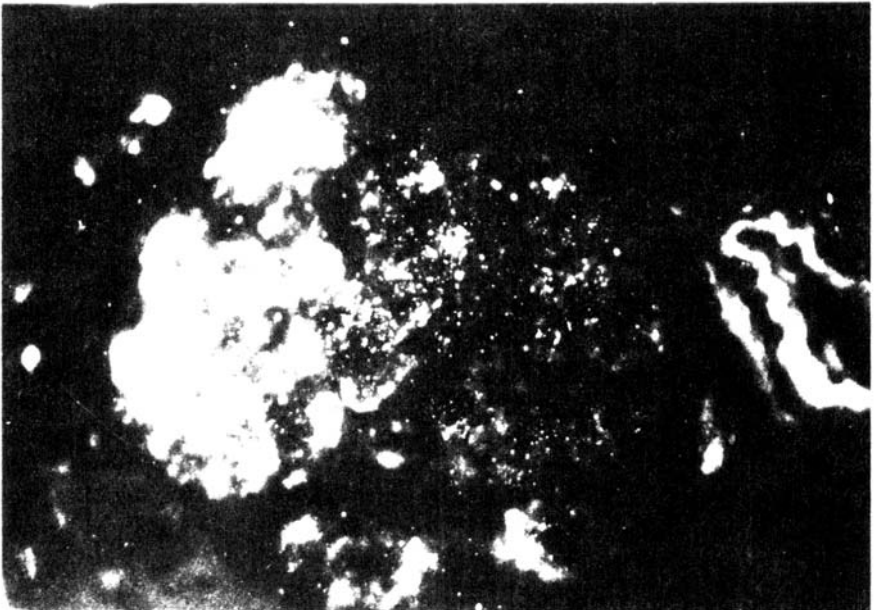


Figure 2. Focal glomerular staining with FAIgG in a case of acute post-streptococcal glomerulonephritis ($\times 290$)

immune deposits in RF positive specimens is indicated in Table II.

Treatment of tissue sections with A/R FAIgG yielded a fluorescence pattern similar to that observed with FAIgG either in EMC (Figure 3A,B) and in the other forms of glomerulonephritis.

TABLE II. Composition of glomerular immune deposits in specimens with RF deposition

Disease	Tissue Specimens No.	Glomerular deposits					
		IgG	IgA	IgM	C ₃	C ₄	Clq
		No. positive					
Acute post-streptococcal GN	6	3	0	2	6	0	1
Crescentic GN	2	1	0	2	2	1	1
Lupus nephritis	4	4	4	4	4	4	4
EMC-GN	8	7	4	8	5	2	4
End-stage kidney disease	1	1	0	1	1	1	1

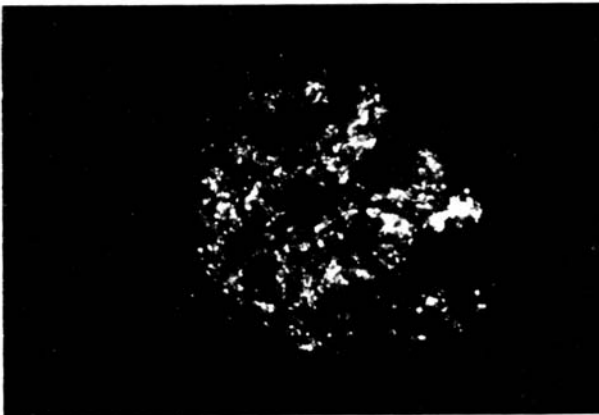


Figure 3A

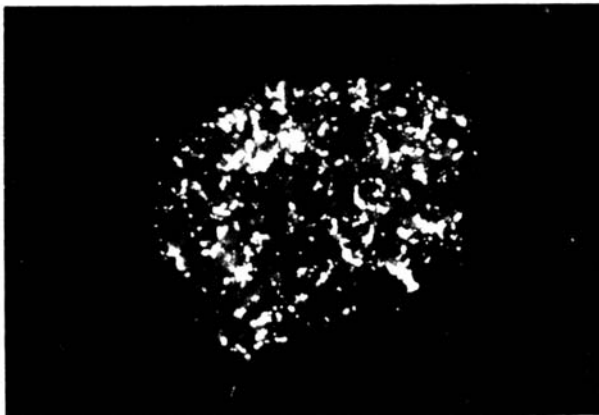

Figure 3B

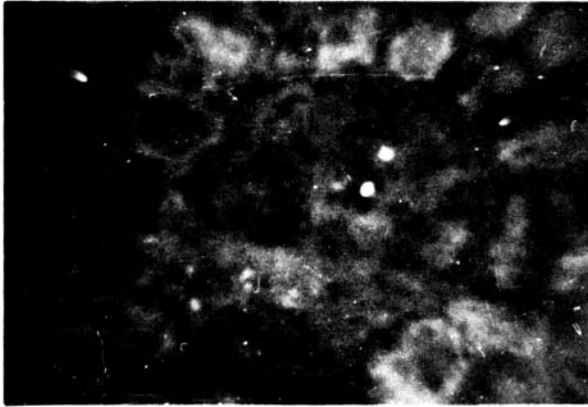


Figure 3C

Figure 3. Serial sections from a specimen with EMC-GN incubated with (A) FAIgG, (B) A/R FAIgG, (C) anti-IgM serum followed by FAIgG ($\times 200$)

Prior incubation of tissue sections with unconjugated anti-IgM antiserum completely inhibited the staining with FAIgG in tissue specimens from patients with EMC glomerulonephritis (Figure 3C). Pretreatment with unconjugated

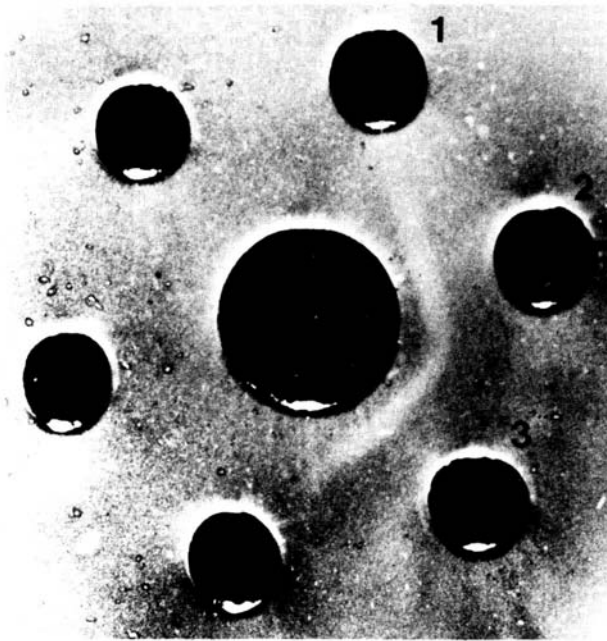


Figure 4. Double diffusion plate: the IgM fraction of the kidney eluate (central well) reacts with both anti-IgM serum (well 2) and anti-kappa serum (well 3). No reaction with anti-lambda serum (well 1)

anti-IgG, anti-IgA, and anti-Clq antisera had no blocking effect. Similar results were obtained in two cases with lupus nephritis where this test was carried out.

After Sephadex G-200 chromatography, the acid eluate of the kidney specimen yielded two fractions containing respectively IgG of kappa and lambda type and IgM reacting with anti-kappa chain antiserum only (Figure 4). In the latex test only the IgM fraction showed RF activity having a titre similar to that of serum cryo-IgM and anti-IgG.

Conclusions

The results of these studies indicate that Rheumatoid Factor participates in the formation of glomerular immune deposits in a high percentage of cases with EMC glomerulonephritis, and in varying proportions of patients with acute post-streptococcal glomerulonephritis, crescentic glomerulonephritis, and lupus nephritis.

In EMC the RF deposits derive from circulating monoclonal RF (Figure 3A to C, and Figure 4). Clearly further studies are needed to assess the role of RF in the genesis of renal tissue damage.

References

- 1 Agnello V, Koffler D, Kunkel HG. *Kidney Int* 1973; 3: 90
- 2 Rossen RD, Reisberg MA, Sharp JT et al. *J Clin Invest* 1975; 56: 427
- 3 Rossen RD, Rickaway RH, Reisberg MA et al. *Arthritis Rheum* 1977; 20: 947
- 4 McIntosh RM, Garcia R, Rubio L et al. *Kidney Int* 1978; 14: 501
- 5 Maggiore Q, Bartolomeo F, L'Abbate A et al. *Kidney Int* 1982; 21: 387
- 6 Dickler HB. *J Exp Med* 1974; 126: 508
- 7 Mizoguchi Y, Tanimoto K, Yue C et al. *Lab Invest* 1979; 40: 703
- 8 Johnston SL, Abraham GN. *Immunology* 1979; 36: 671
- 9 Agnello V, Winchester RJ, Kunkel HG. *Immunology* 1970; 19: 909

Address for correspondence: Dr Filippo Bartolomeo, Centro di Fisiologia Clinica CNR, Via Sbarre Inferiori No. 39, 89100 Reggio Calabria, Italy