

MORPHOLOGIC AND FUNCTIONAL TUBULAR CHANGES IN CHRONIC GLOMERULONEPHRITIS

H Klinkmann*, M Ratner, V V Serov, H Nizze*, B I Rosenfeld,
W Sinn*, R Schmicker*

*Institute of Transplantation and Artificial Organs, Moscow,
Soviet Union, and *Wilhelm-Pieck-University, Rostock, GDR*

Summary

In 135 patients with different glomerular diseases but normal glomerular filtration rates (C_{Cr} and $I_n = 103 \pm 2$ ml/min) correlations between morphological tubular lesions (tic) and changes in tubular function were investigated. Between the extent of tubular lesions and the impairment of specific tubular functions

$$C_{H_2O}; U_{osm_{max}}; U_{NH_4} + V; \frac{U_{NH_4} + V}{V_H + V}$$

exists a highly significant correlation. The combined diminution in $U_{osm_{max}}$ and $U_{NH_4} + V$ reflects in 72 per cent the appearance of a severe tubular lesion and should be used for its clinical recognition.

Introduction

In glomerular diseases tubular changes have long been neglected as a valuable diagnostic tool. Even fewer attempts have been made to correlate the extent of morphological abnormalities with the changes in tubular function.

In 1968 de Wardener's group reported that a highly significant correlation exists between the extent of tubular lesions in glomerular diseases and renal function parameters, long before this correlation becomes evident for the glomerular changes [1].

In 1977 Bohle et al [2, 3] described an alteration of the interstitial volume that could be found in several patients with minimal change lesions and nephrotic syndrome. Jepsen et al [4] confirmed this report and found an even greater degree of interstitial fibrosis in patients with different glomerular diseases.

Our group (Ratner, Klinkman, et al) has studied this problem since 1975 [5, 6].

This study investigates the correlation of morphological lesions of the tubules with tubular function tests which may precede the impairment of glomerular filtration.

Material and Method

This study is based on an analysis of biopsy findings and renal function tests (Table I) in 135 patients with different glomerular diseases (Table II) according to the WHO-classification [7]. A prerequisite to enter the study was a glomerular filtration rate still in the normal range (C_{In} and $C_r > 80$ ml/min). For the purpose of this investigation the patients were subjected to the whole series of tubular function tests (Table I) which thus allowed correlation of specific functions with the morphological lesions in order to assess the specific value of single tests. The methodology of the tubular function tests have been described by us previously [6].

TABLE I. Renal function tests used in this study

Parameter	Reference value (S)	Low limit. value
C_{In} and C_r (ml/min)	110	80
C_{H_2O} (ml/min)	12	10
$U_{osm_{min}}$ (mmol/L)	65	90
$U_{osm_{max}}$ (mmol/L)	1100	850
$U_{NH_4} + V$ (μ mol/min)	63	25
$U_{TA} + V$ (μ mol/min)	33	25
$U_H + V$ (μ mol/min)	96	70
$\frac{U_{NH_4} + V}{U_H + V} \%$	66	40

TABLE II. Classification of glomerular diseases in 135 patients

Histological pattern (WHO 1982)	Number	%
Minimal change nephr. syndrome	1	0.8
Focal/segmental glomerulosclerosis	6	4.4
Diffuse membranous GN	11	8.1
Diffuse mesangial proliferative GN	81	60.0
Diffuse mesangiocapillary GN (Type I)	17	12.6
Diffuse sclerosing GN	19	14.1

Assessment of the histological changes: Figures 1 and 2. In each biopsy specimen special attention was paid to changes in the interstitium and the tubules. Tubular lesions are characterised by fibrous interstitial tissue, oedema and various

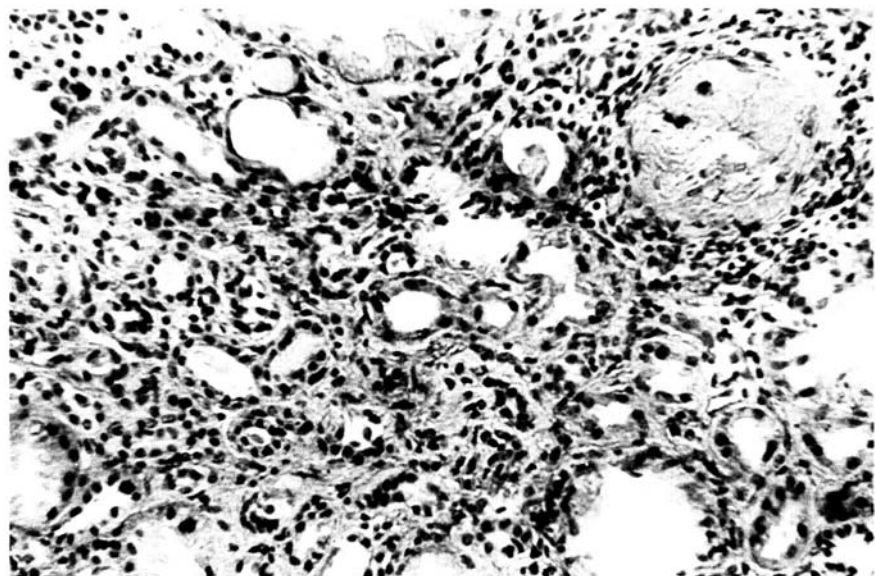


Figure 1. *Tubulointerstitial component* interstitial fibrosis and lymphocytic infiltrates, tubular atrophy; 32-year-old woman with diffuse glomerulonephritis, renal biopsy, Dogmagk 250X (reduced for publication)

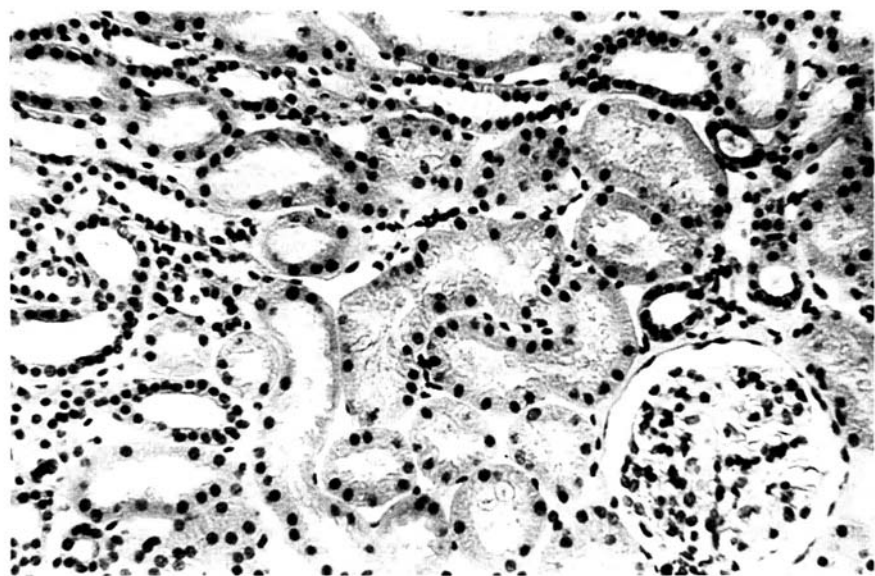


Figure 2. *Control case* no tubulointerstitial component; 20-year-old man with minor glomerular abnormalities; renal biopsy, Dogmagk 250X (reduced for publication)

types of inflammation with basement membrane thickening and diffuse or focal atrophy. These lesions were termed tubular interstitial component (tic). The tic was graded in terms of the extent of these lesions as moderate and severe. These gradings were made independently by two pathologists in Rostock and Moscow.

Results

In 135 patients with glomerular disease but still normal GFR, morphological tubular lesions (tic) were found in 101 (75%) cases – 56=42% with moderate tic (Figure 1), 45=33% with severe tic (Figure 2) – (Figure 3).

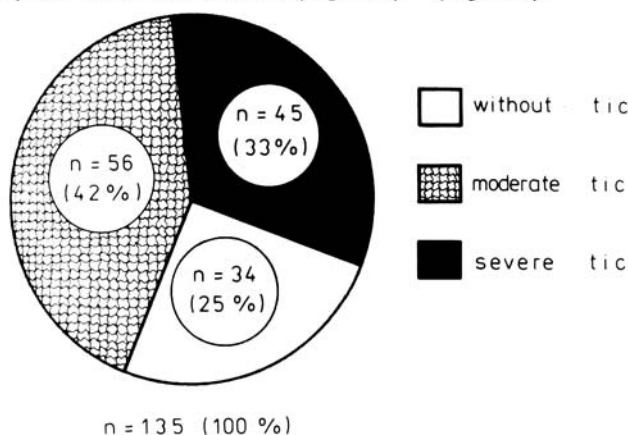


Figure 3. Different degrees of morphological tubular lesions (tic) in 135 patients with glomerular diseases

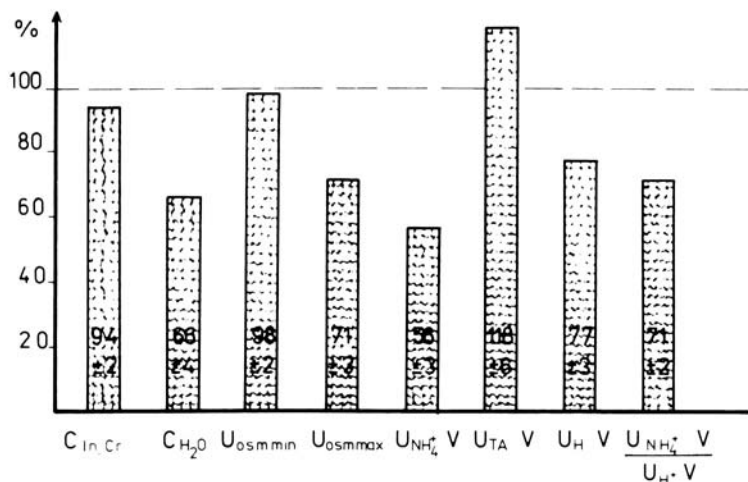


Figure 4. Renal function tests in percentage of the normal reference values (mean values of 135 patients)

There was a significant average decrease in the majority of the tubular function tests (Figure 4).

A statistically highly significant correlation exists between the impairment of specific tubular functions:

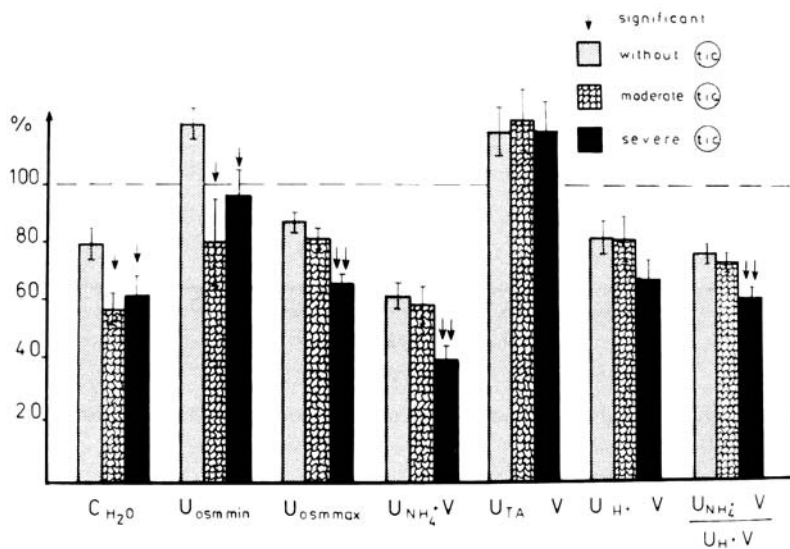


Figure 5. Correlation between tubular function parameters and tic

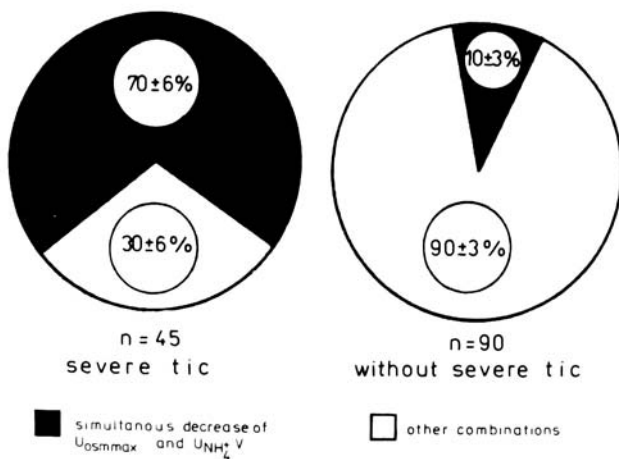


Figure 6. Relationship between simultaneous decrease in $U_{osm\ max}$ and $U_{NH_4^+V}$ and morphological tubular lesions (tic)

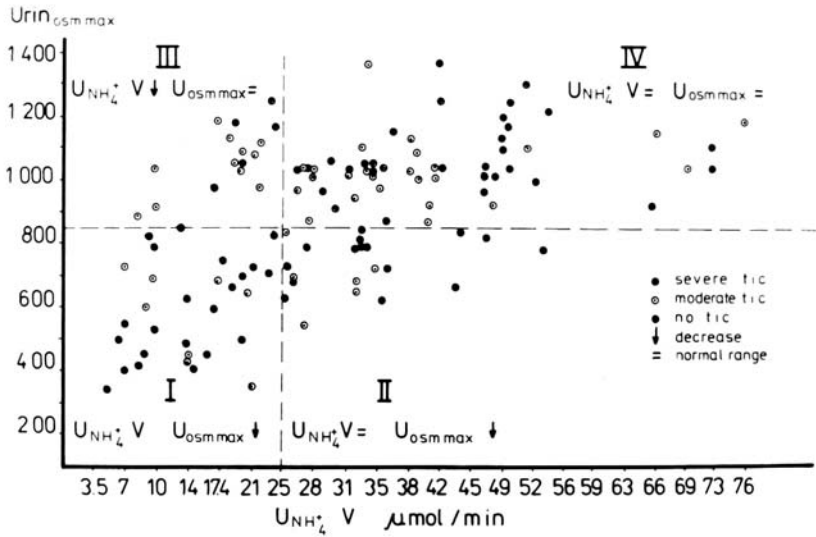


Figure 7. Relationship between selected tubular function tests and morphological tubular lesions (tic)

$$C_{\text{H}_2\text{O}}; U_{\text{osmmax}}; U_{\text{NH}_4} + V; \frac{U_{\text{NH}_4} + V}{V_{\text{H}} + V}$$

and the extent of the tubular interstitial component (Figure 5).

We found a particularly close and highly significant correlation between the degree of the tic and the combined deterioration of U_{osmmax} and $U_{\text{NH}_4} + V$ in our series (Figures 6 and 7).

Conclusions

Information derived from this study indicates that in glomerular diseases impairment of tubular function is a relatively early symptom and may precede the decrease in glomerular filtration rate. Morphological tubular lesions (tic) as an early sign in glomerular disease should always lead to a thorough search for further focal or segmental lesions.

The results of this study make it obvious that significant correlations exist between the impairment of specific tubular functions and the degree of morphological tubular lesions (tic). The combined diminution of U_{osmmax} and $U_{\text{NH}_4} + V$ reflects the appearance of a severe tic as an early morphological change in glomerular diseases and should be used for its clinical recognition.

In the early stage of glomerular disease the structural damage (tic) in the tubules may much more influence the overall renal function as indicated by impaired tubular function tests. The evidence available at this moment does not permit us yet to determine whether these results are of further value, for example

in the prognosis of the disease or in monitoring treatment.

The significant correlation of morphological changes with early deterioration in basic tubular function tests justifies, in our opinion, further detailed study as a different approach for a useful combination between morphological and clinical findings during the course of the disease.

References

- 1 Risdon RA, Sloper JC, de Wardener HE. *Lancet* 1968; ii: 363
- 2 Bohle A, Grund KE, Mackensen S, Tolon M. *Virchows Arch (Path Anat)* 1977; 373: 15
- 3 Bohle A, Glomb D, Grund KE. *Virchows Arch (Path Anat)* 1977; 376: 221
- 4 Jepsen FL, Mortensen PB. *Virchows Arch (Path Anat)* 1979; 383: 265
- 5 Ratner MYa, Serov VV. *Z Urol u Nephrol* 1975; 68: 913
- 6 Ratner MYa, Serov VV, Tomilina NA. *Z Urol u Nephrol* 1976; 69: 173
- 7 Churg J, Sobin LH, eds. *Renal Diseases, Classification and Atlas of Glomerular Diseases* 1982. Tokyo, New York: Igaku Shoin

Address for correspondence: H Klinkmann, Department of Internal Medicine, Wilhelm-Pieck-University, Rostock, GDR